



Akreditasi PB IDI-2 SKP

# Cutaneous Mucormycosis

**Erlinda Karyadi, Leoni Agnes**

Faculty of Medicine, Maranatha Christian University, Bandung, Indonesia

## ABSTRACT

Cutaneous mucormycosis is an emerging fungal infection caused by opportunistic fungi from phylum Glomeromycota. This disease is frequently found in poorly controlled diabetic patients and immunosuppressed individuals. It is usually acquired by direct inoculation through trauma. The clinical presentation is nonspecific indurated plaque rapidly evolves to necrosis. Diagnosis should be confirmed by demonstration of the etiological agent and molecular tests. First-line therapy is amphotericin B combined with surgery; second line treatment include posaconazole and isavuconazole.

**Keywords:** Cutaneous mucormycosis, rhizopus, zygomycosis

## ABSTRAK

*Cutaneous mucormycosis* adalah infeksi jamur oportunistik dari film *Glomeromycota*. Penyakit ini sering dijumpai pada pasien diabetes tidak terkontrol serta pada pasien imunosupresi. Penyebaran penyakit ini umumnya inokulasi langsung melalui trauma. Gambaran klinis berupa plak berindurasi nonspesifik yang berkembang cepat menjadi nekrosis. Diagnosis melalui pemeriksaan kultur dan sejumlah tes molekular. Terapi lini pertama yaitu *amphotericin B* dengan pembedahan, lini kedua dapat menggunakan *posaconazole* dan *isavuconazole*. **Erlinda Karyadi, Leoni Agnes. Cutaneous Mucormycosis**

**Kata kunci:** *Cutaneous mucormycosis, rhizopus, zygomycosis*

## INTRODUCTION

Mucormycosis (previously called Zygomycosis) is the term used for invasive fungal infections (IFIs) due to saprophytic environmental fungi - *Rhizopus* (most common), *Mucor*, *Cunninghamella*, *Aposphysomyces*, *Lictheimia (Absidia)*, *Saksenaea*, *Rhizomucor*.<sup>1</sup> Mucormycosis can have at least six different clinical presentations - rhinocerebral, pulmonary, cutaneous, gastrointestinal, disseminated and miscellaneous.<sup>2</sup> Cutaneous mucormycosis is the third most common manifestation (after rhinocerebral and pulmonary) and is seen in 19% mucormycosis patients.<sup>1</sup>

The common risk factors for mucormycosis include hematologic malignancies, solid organ transplant recipients (SOTRs), stemcell transplantation, prolonged and severe neutropenia, poorly controlled diabetes mellitus (DM), iron overload, deferoxamine

therapy, major trauma, prolonged corticosteroid use, illicit intravenous drug use, neonatal prematurity, malnutrition and potential nosocomial sources (including bandages and intravascular devices).<sup>1,3,4</sup> Mucormycosis comprises 2-6% of IFIs.<sup>4,5</sup> Multi-center prospective TRANSNET study reported that the cumulative incidence of mucormycosis was 0,07% in SOTRs at the end of one year.<sup>5</sup>

### Epidemiology

In developed countries, mucormycosis frequently present after allogeneic hematopoietic stem cell transplantations and in other hematologic malignancies. While in developing countries, uncontrolled diabetes mellitus is the main associated disease.<sup>6</sup>

Its global incidence was 0,43 cases per million per year in 2005. In France, between 1997 and 2006, there was an increase from 0,7 to 1,2 cases per million, mainly in patients with

hematologic malignancies and bone marrow transplantation.<sup>6</sup> There are no extensive prospective reports in the United States of America; the incidence was 1,7 cases per million per year in the state of California.<sup>6</sup>

Zygomycetes are ubiquitous in nature and are usually isolated from decaying organic matter, soil, wood, cotton, bread, fruits, vegetables, and animal excreta.<sup>7</sup> Primary cutaneous mucormycosis is often acquired by direct inoculation, contaminated dressings, surgery, burns, motor vehicle accidents, and insulin injection sites.<sup>6</sup> There are report of outbreaks of mucormycosis in healthcare centers due to contaminated adhesive tape, wooden tongue depressors, ostomy bags, and building construction contamination.<sup>6,8,9</sup> Other reports associated this fungus with vascular devices and nitroglycerine patches.<sup>6,10</sup> In a review of 196 healthcare-associated mucormycosis cases, 57% involved the skin.<sup>4</sup> Predominant

**Alamat Korespondensi** email: [erlindakaryadi19@gmail.com](mailto:erlindakaryadi19@gmail.com), [leoniagnesdr@gmail.com](mailto:leoniagnesdr@gmail.com)



populations were premature infants, surgical patients, and immunocompromised hosts.<sup>4</sup> According to the largest review of reported cases, the age of presentation ranges from months to 87 years with a mean of 38 years. It is more frequent in men with a ratio of 1,1:1.<sup>1,11,12</sup>

### Risk Factor

The classic major risk factors are uncontrolled diabetes and ketoacidosis, but more recently, hematological malignancies and allogenic hematopoietic stem cell transplantation have become more frequent risk factors.<sup>6</sup> Other underlying conditions are solid organ transplantation, deferoxamine therapy, drug injections, renal failure, infant low birth weight, malnutrition, HIV infection, systemic lupus erythematosus, burns, trauma, aplastic anemia, and steroid use.<sup>6</sup>

Mucormycosis can also occur in patients with no predisposing factors. According to Roden et al, there is no underlying condition in 50% cutaneous mucormycosis cases;<sup>1</sup> in another review, 40% patients were immunocompetent.<sup>8</sup>

### Etiopathogenesis

The fungi responsible for mucormycosis, also called zygomycosis, were previously classified in the class Zygomycetes, order Mucorales. Zygomycetes also include order Entomophthorales, which are responsible for entomophthoromycosis. Recently, molecular phylogenetic analyses have found that Zygomycota are polyphyletic, and these fungi have been placed into the new monophyletic phylum called Glomeromycota, with the subphyla Mucormycotina and Entomophthoromycotina. In this context, the names "mucormycosis" and "entomophthoromycosis" should be preferred, and zygomycosis should be dismissed.<sup>6</sup>

Most clinical isolates belong to the genera *Rhizopus*. In reviews of cutaneous mucormycosis, the most frequent isolated strains are *Rhizopus oryzae*, *Lichtheimia corymbifera* and *Apophysomyces elegans*. Other isolates reported are *Mucor* sp, *Saksenaia vasiformis*, *Cunninghamella bertholletiae*, *Rhizomucor* spp, and *Rhizopus microsporus*. In Mexico, there is a case report of a new species *Apophysomyces mexicanus*.<sup>13</sup>

Mucormycosis is not contagious, it cannot be passed from one person to another. Human infection is through contact with fungal spores in the atmosphere. If the spores is inhaled, it may invade lungs or sinuses. Skin fungal infection may form if the fungi enter the body through a bite, scratch, or burn. The infection will then spread to organs mostly the eye, brain, heart, and spleen via bloodstream.<sup>14</sup> Mucormycosis outbreaks has been attributed to adhesive bandages, wooden tongue depressors, hospital linens, negative pressure spaces, water leaks, inadequate air filtration, and non-sterile equipment in healthcare.<sup>15</sup> Natural disasters have also been attributed to community-onset outbreaks.<sup>15</sup>

### CLINICAL MANIFESTATION

Cutaneous mucormycosis can be primary and secondary. Primary form developed after direct spores inoculation to the dermis and secondary form developed via dissemination to other location such as rhino-orbital-cerebral infection, pulmonary infections, and gastrointestinal infections.<sup>16,17</sup> The primary form often occurs in patients with burns, skin major/minor trauma, or direct inoculation of spores in open wound. The entry into the dermis may be attributed to the use of contaminated dressings, bandages and splints, surgical site, and needles or intravenous access device.<sup>7,18,19</sup>

Cutaneous mucormycosis is subcategorized as localized disease, deep extension infection with invasion into muscle, tendon or bone, and disseminated infection involving another non-contiguous site.<sup>16,21</sup> Mostly, the disease remain localized, 24% with deep extension infection, and 20% disseminate to non-contiguous site.<sup>7,16</sup>

Any area of the skin can be affected by mucormycosis. Commonly, it appear in upper and lower extremities; there have been reports of cutaneous zygomycosis of the scalp, face, breast, thorax, back, abdomen, gluteal area and perineum.<sup>7,16</sup>

The clinical presentation usually appears as a single, painful, erythematous and indurated cellulitis that progresses to a necrotic lesion with erythematous halo that develops into ecthyma-like lesion. Other forms could be presented as abscesses, skin swelling, tinea corporis-like lesion (superficial lesion with squamous borders), erythema multiform-like lesion (targetoid plaques with outer

erythematous rims and echymotic or blackened necrotic centres), and lesions with a cotton-like appearance resembling bread mould (Figures 1,2,3).<sup>7,16,18,20</sup>

The lesion may rapidly progress to form necrotizing fasciitis and gangrene caused by hyphae invasion to the vessels. Disseminated disease may show general signs and symptoms of sepsis.<sup>7,16,21</sup>

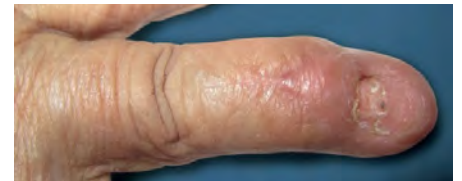

Figure 1. Cutaneous lesion of mucormycosis.<sup>16</sup>

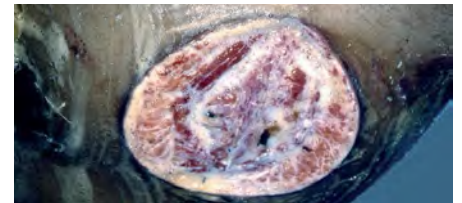


Figure 2. Cutaneous lesion of mucormycosis.<sup>16</sup>

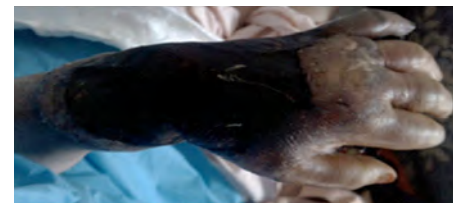

Figure 3. Rapidly progressive skin and deep soft tissue necrosis of the hand and forearm.<sup>20</sup>

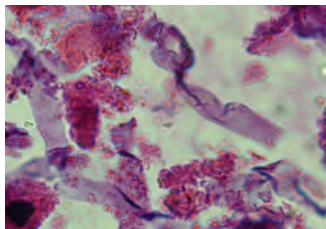
### Differential Diagnosis

Cutaneous mucormycosis lesions may mimic pyoderma gangrenosum, bacterial synergistic gangrene, tinea corporis or other infections by *Pseudomonas*, *Aspergillus*, *Histoplasma*. It also may mimic autoimmune disorders, drug reactions, infiltrative diseases, and neoplastic disorders.<sup>7,16,22</sup>

### DIAGNOSIS

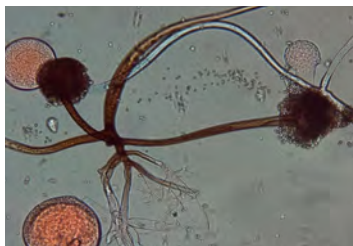Early identification of cutaneous mucormycosis is essential to establish prompt antifungal treatment and improve outcome. Every necrotic lesion that doesn't improve with broad spectrum antibiotic therapy should be suspected as mucormycosis. Diagnosis is by organisms identification through biopsy for histopathology and culture. The biopsy specimen should be

taken from the centre of the lesion and include subcutaneous fat, because moulds frequently invade blood vessels of the dermis and subcutis, resulting in an ischaemic cone at the skin surface. Impression smears from wound edges may also help diagnosis. Histopathological findings are characterized by broad, mostly aseptate bifurcated hyphae in the dermis, with irregular branching that occasionally occurs at right angle, often invading the vessel walls with subsequent thrombosis and infarction of arterioles and tissue hemorrhage of venules. The inflammatory reaction is variable, and hyphal fragments are often engulfed by multinucleated giant cells (Figure 4).<sup>7,17,21</sup>



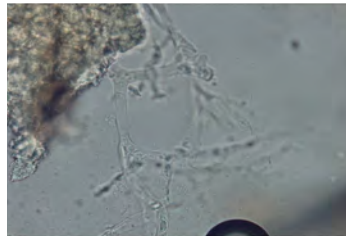
**Figure 4.** Histopathology study from biopsy specimen showed broad, aseptate, and thin walled fungal hyphae (H&E x400).<sup>20</sup>

Fungal cultures are positive in 50% cases, recent reviews reported an increase in culture positivity from 72% to 89% in cutaneous locations.<sup>16</sup> *Rhizopus* spp. is one of the most common pathogen in positive specimens.<sup>20</sup> Cultures must be performed in Sabouraud and potato dextrose agar media, avoiding media with antibiotics that may inhibit fungus growth (Figure 5).<sup>16,20</sup>



**Figure 5.** Lactophenol cotton blue (LPCB) mount of growth of *Rhizopus* spp. on Sabouraud's dextrose agar without cycloheximide.<sup>20</sup>

Direct KOH microscopic examination can observe the presence of non-septated, hyaline, hyphae, 5 µm wide and 20 to 50µm long, with irregular branching at right angles, mainly at the periphery of the lesion (Figure. 6). Impression smears from the wound edges may also be useful.<sup>2,3</sup>



**Figure 6.** Microscopic features of mucormycosis - after treated with 10% KOH; showed broad nonseptate hyphae (x400).<sup>20</sup>

PCR-based approaches have shown promise for diagnosis with high sensitivity and specificity. These include PCR assays, PCR/HRM analysis, and PCR/electrospray ionization mass spectrometry (PCR/ESI-MS). Almost all of these assays targeted the amplification of either internal transcribed spacer 1 (ITS1) or ITS2 or 18S-28S ribosomal rRNA genes.<sup>23,24</sup> The sensitivity/specificity of the primers were determined either from gDNA extracted from Mucorales grown in cultures by rolling cycle amplification technique without confirming the findings in biological samples, or with formalin-fixed, paraffin-embedded biopsy specimens which usually reduces the sensitivity of the assay (56%).<sup>23</sup> The use of unfixed tissue to diagnose mucormycosis using PCR/ESI-MS was recently shown to be more effective in identifying Mucorales to the species level than qPCR, ITS PCR, and 18S PCR.<sup>25</sup> *CotH* genes were suitable biomarkers for a rapid, simple, and reliable diagnostic PCR-based assay for mucormycosis.<sup>23</sup>

**TREATMENT**

Management of cutaneous mucormycosis include early diagnosis, correction of the underlying metabolic or impaired immunological status, control of other

concomitant infections, prompt administration of antifungal therapy, and surgical debridement (Table).<sup>7,16,18,21</sup>

First line treatment is monotherapy with amphotericin B. The antifungal of choice is deoxycolate amphotericin B (d-AmB), often substituted with lipid formulations for better safety profile; allowing longer treatment periods with higher doses. In immunocompromised patients, the recommended dose for d-AmB is 1-1.5mg/kg/day, for liposomal amphotericin B (L-AmB), the initial starting dose is 5 mg/kg IV daily, with a maximum dose of 10 mg/kg IV and 5 mg/kg/day for amphotericin B lipid complex.<sup>16,18,21</sup> Dose increase does not result in higher plasma levels. The lipid formulation of amphotericin B is administered in high doses intravenously once a day as initial therapy. Treatment must be started within the first 5 days after clinical diagnosis to increase survival. Improvement of comorbidities is imperative. Treatment duration depends on clinical picture.<sup>7</sup> Some authors recommend continuing AmB until clinical and radiological resolution<sup>26</sup>, others recommend 6 to 8 weeks.<sup>27</sup>

Posaconazole and isavuconazole are alternatives for amphotericin B. Posaconazole is recommended as second-line treatment for patients with refractory disease or intolerance to AmB or for those who need prolonged treatment maintenance.<sup>16</sup> The suggested dose is 400mg bid, and in most reported cases therapy is provided for several months.<sup>16</sup> For salvage treatment, posaconazole 200 mg IV four times daily is recommended.<sup>18</sup> Isavuconazole has recently been successfully used as salvage therapy in immunocompromised patients with pulmonary, rhinocerebral, and in disseminated mucormycosis refractory to AmB and posaconazole.<sup>32</sup> Recently a multicenter, clinical, single arm, open-label trial was conducted on 34 invasive mucormycosis patients, using isavuconazole for a median of 84 days. At the end of treatment, 5 patients presented complete response, 6 with partial response, 10 stable, and 15 with disease progression.<sup>16</sup>

**Table.** Treatment of mucormycosis.<sup>16</sup>

Antifungal Therapy		Non-pharmacological Treatments	
AmB deoxycholate	IV	Standard dose 0.25 - 0.75mg/kg/per day	Control underlying conditions
		Severe cases 1.0 – 1.5mg/kg/per day	Surgery of soft tissue rhino-orbito-cerebral disease
Liposomal AmB	IV	5 – 10mg/kg/per day	
AmB Lipid Complex	IV	5 – 7mg/kg/per day	
Posaconazole	PO	400mg bid	



Early surgical debridement of the infected tissue should be urgently performed to limit further spread of infection that may involve amputation of the disease site.<sup>16,18,20</sup>

### PROGNOSIS

Prognosis of cutaneous zygomycosis is dependent upon the timing of therapeutic intervention, as well as the degree of the underlying immunodeficiency of the patient. In one analysis, mortality was 10% for localized

infection, 26% for cutaneous zygomycosis with deep extension, and 94% for disseminated disease. In a 2005 to 2008 review, the respective rates were 4.0%, 29.0%, and 83.0%,<sup>3</sup> whereas in the present review they were 5.5%, 43.0% and 50.0% for localized infection, infection with deep extension, and disseminated disease, respectively.<sup>28</sup> Risk factors include disseminated infection, renal injury, central nervous system disease, and inadequate response to medical treatment indicate poor prognosis.<sup>18</sup>

### CONCLUSION

Cutaneous mucormycosis is a very aggressive invasive fungal infection. The clinical presentation usually is very rapidly progressive lesion and the presence of tissue necrosis. Early biopsy must be done immediately. First-line therapy is amphotericin B combined with surgery; second line treatment include posaconazole and isavuconazole. Controlling underlying conditions is also an important aspect of therapy. Earlier diagnosis and treatment improve outcome.

### REFERENCES

1. Roden MM, Zoutis TE, Buchanan WL, Knudsen TA, Sarkisova TA, Schaufele RL, et al. Epidemiology and outcome of zygomycosis: A review of 929 reported cases. *Clin Infect Dis* 2005;41:634-53.
2. Spellberg B, Edwards Jr J, Ibrahim A. Novel perspectives on mucormycosis: Pathophysiology, presentation, and management. *Clin Microbiol Rev*. 2005;18(3):556-69.
3. Petrikkos G, Skiada A, Lortholary O, Roilides E, Walsh TJ, Kontoyiannis DP. Epidemiology and clinical manifestations of mucormycosis. *Clin Infect Dis*. 2012;54(1):23-34.
4. Rammaert B, Lanternier F, Zahar JR, Dannaoui E, Bougnoux ME, Lecuit M, et al. Healthcare-associated mucormycosis. *Clin Infect Dis* 2012;54(Suppl 1):44-54.
5. Pappas PG, Alexander BD, Andes SR, Hadley S, Kauffman CA, Freifeld A, et al. Invasive fungal infections among organ transplant recipients: Results of the transplant-associated infection surveillance network (TRANSNET). *Clin Infect Dis*. 2010;50(8):1101-11.
6. Castrejón-Pérez AD, Welsh EC, Miranda I, Ocampo-Candiani J, Welsh O. Cutaneous mucormycosis. *An Bras Dermatol*. 2017;92(3):304-11.
7. Skiada A, Rigopoulos D, Larios G, Petrikkos G, Katsambas A. Global epidemiology of cutaneous zygomycosis. *Clin Dermatol*. 2012;30:628-32.
8. Skiada A, Petrikkos G. Cutaneous zygomycosis. *Clin Microbiol Infect*. 2009;15:41-5.
9. Lalayanni C, Baliakas P, Xochelli A, Apostolou C, Arabatzis M, Velegriki A, et al. Outbreak of cutaneous zygomycosis associated with the use of adhesive tape in haematology patients. *J Hosp Infect*. 2012;81:213-5.
10. Simbli M, Hakim F, Koudieh M, Tleyjeh IM. Nosocomial post-traumatic cutaneous mucormycosis: A systematic review. *Scand J Infect Dis*. 2012;54:44-54.
11. Skiada A, Pagano L, Groll A, Zimmerli S, Dupont B, Lagrou K, et al. Zygomycosis in Europe: Analysis of 230 cases accrued by the registry of the European Confederation of Medical Mycology (ECMM) Working Group on Zygomycosis between 2005 and 2007. *Clin Microbiol Infect*. 2011;17:1859-67.
12. Bitar D, Van Cauteren D, Lanternier F, Dannaoui E, Che D, Dromer F, et al. Increasing incidence of zygomycosis (mucormycosis), France, 1997-2006. *Emerg Infect Dis*. 2009;15:1395-401.
13. Bonifaz A, Stchigel AM, Guarro J, Guevara E, Pintos L, Sanchis M, et al. Primary cutaneous mucormycosis produced by the new species *Apophysomyces mexicanus*. *J Clin Microbiol*. 2014;52:4428-31.
14. Isha B, Amjad B, Fareeda A. A contemporary intimidation for COVID-19 patients coinfecting with mucormycosis in India. *J Bacteriol Mycol Open Access*. 2021;9(2):69-71.
15. Ibrahim AS, Spellberg B, Walsh TJ, Kontoyiannis DP. Pathogenesis of mucormycosis. *Clin Infect Dis*. 2012;54 (Suppl 1):16-22.
16. Castrejón-Pérez AD, Welsh EC, Miranda I, Ocampo-Candiani J, Welsh O. Cutaneous mucormycosis. *An Bras Dermatol*. 2017;92(3):304-11.
17. Sittig KR, Laageide LG, Akhtar Z, Wall GC, Kumar SC. Cutaneous mucormycosis in a chronic lymphocytic leukemia patient on ibrutinib. *IDCases*. 2021;24:e01120.
18. Hernández JL, Buckley CJ. Mucormycosis. In: *StatPearls* [Internet]. Treasure Island (FL): StatPearls Publishing; 2021. Available from: <https://www.ncbi.nlm.nih.gov/books/NBK544364/>
19. Jeong W, Keighley C, Wolfe R, Lee WL, Slavin MA, Kong DCM, et al. The epidemiology and clinical manifestations of mucormycosis: A systematic review and meta-analysis of case reports. *Clin Microbiol Infect*. 2019;25(1):26-34.
20. Ahmadinejad Z, Khazraian H, Ghanbari F, Ahmadi B, Shoar MG. Cutaneous mucormycosis in a diabetic patient following traditional dressing. *Case Rep Dermatol Med*. 2013 ;2013:894927. doi: 10.1155/2013/894927..
21. Menzinger S, Sid'Amar S, Kaya G. Cutaneous mucormycosis resulting from hematogenous dissemination of *Rhizomucor pusillus* in an immunocompromised patient. *Dermatopathol*. 2019;6:275-8.
22. Jia QY, Song YG, Li XQ, Mu ZL, Li RY, Li HM. Simultaneous infection of the skin surface and dermal tissue with two different fungus mimicking pyoderma gangrenosum: A case report. *Clin Cosmet Investig Dermatol*. 2021;14:163-7
23. Baldin C, Soliman SSM, Jeon HH, Alkhazraji S, Gebremariam T, Gu Y, et al. PCR-based approach targeting mucorales-specific gene family for diagnosis of mucormycosis. *J Clin Microbiol*. 2018;56(10):746-18.
24. Ziaee A, Zia M, Bayat M, Hashemi J. Molecular identification of mucor and lichtheimia species in pure cultures of zygomycetes. *Jundishapur J Microbiol*. 2016;9(4):35237.
25. Alanio A, Garcia-Hermoso D, Mercier-Delaurie S, Lanternier F, Gits-Muselli M, Menotti J, et al. Molecular identification of mucorales in human tissues: Contribution of PCR electrospray-ionization mass spectrometry. *Clin Microbiol Infect*. 2015;21:594.
26. Blyth CC, Gilroy NM, Guy SD, Chambers ST, Cheong EY, Gottlieb T, et al. Consensus guidelines for the treatment of invasive mould infections in haematological malignancy and haemopoietic stem cell transplantation. *Intern Med J*. 2014;44:1333-49.
27. Skiada A, Lanternier F, Groll AH, Pagano L, Zimmerli S, Herbrecht R, et al. Diagnosis and treatment of mucormycosis in patients with hematological malignancies: Guidelines from the 3rd European Conference on Infections in Leukemia (ECIL 3). *Haematologica*. 2013;98(4):492-504.
28. Sipsas NV, Gamaletsou MN, Anastasopoulou A, Kontoyiannis DP. Therapy of mucormycosis. *J Fungi (Basel)*. 2018;4(3):90.