



# Diagnosis of Jejuno-ileal Atresia vs. Malrotation-associated Midgut Volvulus in Neonates

Ovamelia Julio,<sup>1</sup> Irene Lokananta,<sup>2</sup> Hing Theddy<sup>1</sup>

<sup>1</sup>Lewoleba General Hospital, Lembata, <sup>2</sup>Prof. Dr. W.Z. Johannes General Hospital, Kupang, East Nusa Tenggara, Indonesia

## ABSTRACT

**Background.** In developing countries, diagnosis and treatment of congenital anomaly in neonates is quite challenging due to limited facilities and resources. **Case.** A 3 day-old male neonates with clinical presentation of small bowel obstruction and suspected jejuno-ileal atresia in plain abdominal radiograph. Volvulus-associated congenital malrotation with gangrenous intestines was found during surgical exploration. Resection was performed and Bishop-Koop procedure was done. Patient's condition was deteriorated and succumbed to sepsis on day-three post-operative. **Conclusion.** This case illustrates potential pitfalls in clinical presentation and interpretation of plain abdominal radiographs that may negatively impact the management of neonatal obstructive ileus.

**Keywords:** Intestinal atresia, malrotation, neonates, pitfalls, volvulus

## ABSTRAK

**Latar Belakang.** Diagnosis dan tatalaksana kelainan kongenital pada neonatus di beberapa negara berkembang cukup sulit karena keterbatasan fasilitas dan sumber daya. **Kasus.** Neonatus laki-laki berusia 3 hari dengan gejala klinis obstruksi usus halus dan gambaran foto polos abdomen mengarah pada atresia jejunoileal. Intraoperatif dijumpai volvulus disebabkan malrotasi kongenital disertai gangren usus. Dilakukan reseksi usus dan prosedur Bishop-Koop. Kondisi pasien memburuk dan meninggal karena sepsis pada hari ketiga post-operasi. **Simpulan.** Kasus ini menggambarkan beberapa potensi *pitfalls* dalam interpretasi gejala klinis dan foto polos abdomen yang dapat berdampak negatif pada penanganan. **Ovamelia Julio, Irene Lokananta, Hing Theddy. Diagnosis Atresia Jejuno-ileal vs. Volvulus Midgut terkait Malrotasi pada Neonatus**

**Kata kunci:** Atresia intestinal, malrotasi, neonatus, *pitfalls*, volvulus

## Introduction

One of the most common congenital anomalies in neonates is intestinal obstruction; causes of small bowel obstruction in neonates include atresia, malrotation, Hirschsprung disease, and other rare causes like congenital band and obstructed hernia.<sup>1</sup> Technology advances in medicine have provided many improvements in diagnosis and treatment, especially in neonates with congenital anomaly. However, large areas still have limited settings and resources that resulted in problematic diagnosis and treatment. Referral issues also add to this problem.

Neonatal intestinal obstruction is conventionally defined as intestinal obstruction from duodenum to anal canal.<sup>1,2</sup> It represents a rather small case but responsible for most surgeries in neonates.<sup>1,2</sup> It commonly

presents with abdominal distention and vomiting.<sup>3-5</sup>

Atresia contributes to more than one-third of neonatal intestinal obstruction cases with jejunal atresia as the second most common cause.<sup>6,7</sup> Malrotation occurs in 1 in 500 live births or about 0,5% population.<sup>1</sup> The case may be asymptomatic, but is associated with increased risk of volvulus - an emergency requiring early diagnosis and treatment.<sup>1</sup>

A case of volvulus associated with malrotation in a neonate was presented; the plain abdominal radiographs indicate jejuno-ileal atresia. A difference between initial diagnosis with intra-operative findings was found.

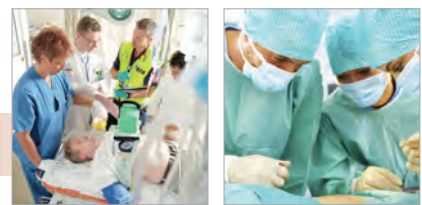## Case

A 3-day-old full-term male neonate was

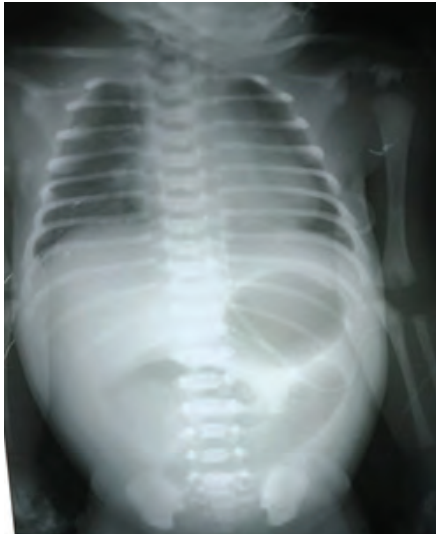brought to the emergency department with persistent bilious non bloody vomiting. His mother had several antenatal cares with local midwife. He was born by normal spontaneous vaginal delivery without complications and managed to pass meconium within 24 hours of life. He was breast-fed well before to discharge on day 2 and continued passing stools at home.

On physical examination, the vital signs were normal except for elevated body temperature due to dehydration. Abdominal examination revealed distention with decreasing bowel sound. He also passed pale stool. Laboratory findings showed no abnormalities while plain abdominal radiograph showed a distended stomach with multiple intestinal loops indicating a jejuno-ileal atresia. A diagnosis of high intestinal obstruction due to suspected

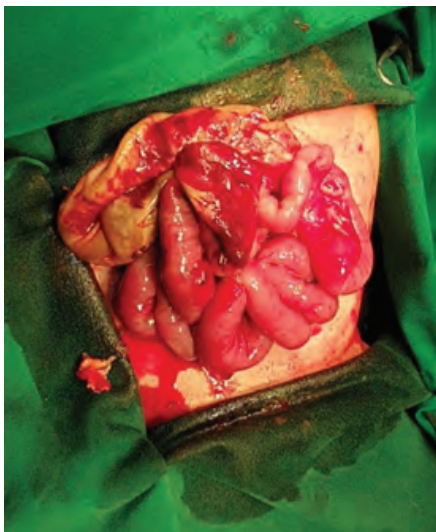
**Alamat Korespondensi** email: ovamelia1207@yahoo.com



jejuno-ileal atresia was made. An orogastric tube was placed and total parenteral nutrition was given.



**Figure 1.** Abdominal plain radiograph showed distended stomach with overlapped multiple intestinal loops



**Figure 2.** Intraoperative showed gangrenous intestines

The patient was referred to a pediatric surgeon and exploratory laparotomy was performed on the fourth day. Intra-operatively, feces

were found intraperitoneally with volvulus-associated 90° intestinal malrotation resulting in a 40 cm gangrenous intestine. Intestinal resection was performed at 8 cm distal of the ligament of Treitz and Bishop-Koop procedure was done. Post-operative, the patient was transferred to the neonatal intensive care unit with ventilator support. On day 3 post-operative, the condition was deteriorated and succumbed to sepsis.

### Discussion

Intestinal malrotation is described as abnormal loops position within the peritoneal cavity.<sup>8</sup> Intestinal malrotation has an abnormal short mesenteric root which predisposes the small bowel to twist around and lead to midgut volvulus. The incidence of malrotation is 18,09% among all cases of small intestinal obstruction.<sup>8</sup> Most cases (85%) present in the first two weeks of life.<sup>8</sup> Clinical signs of malrotation are bilious vomiting with or without abdominal distention and possible bloody stool due to ischemia.<sup>1,4</sup>

Intestinal atresia is one of the most common causes of intestinal obstruction in neonates. Most atresia is duodenal atresia, followed by jejunoileal atresia. It is more common in males than females.<sup>4</sup> Clinical signs of intestinal atresia are similar to intestinal malrotation. It may present within 24 hours to several days of life.<sup>4</sup> The case showed a clinical presentation of intestinal obstruction. He also passed pale stool with no abnormality of liver function. This condition may present in jejunoileal atresia.<sup>9,10</sup>

Intestinal atresia may be diagnosed with prenatal ultrasound.<sup>11</sup> However, diagnosis of jejunoileal atresia is still difficult. Prenatal ultrasound findings of polyhydramnion with vague abdominal imaging increase suspicion of congenital anomaly.<sup>11</sup> Careful history taking and physical examination should be done to differentiate those conditions; plain radiographs are often diagnostic.<sup>11</sup>

Plain abdominal radiograph of duodenal atresia shows double bubble sign with gasless distal bowel while jejuno-ileal atresia shows distended stomach by gases, multiple air fluid level with the absence of distal bowel gas shown in this case.<sup>6,12,13</sup> In malrotation, abnormal location of small and large bowel might be found in a plain radiograph. The most common plain radiograph finding in malrotation is normal bowel gas pattern; but some volvulus associated with malrotation cases showed gasless abdomen or 'coffee bean' appearance.<sup>3,4,13,14</sup>

Patient with clear signs and radiograph findings should be treated accordingly and might not need further examination. Otherwise, the upper gastrointestinal radiological examination might be performed as the gold standard for diagnosis of malrotation associated with volvulus.<sup>11,15</sup> However gastrointestinal contrast was not available in some limited settings area like in our hospital.

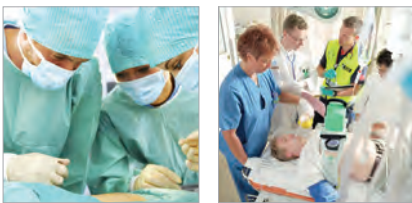In this case, the clinical presentation of acholic stool and abdominal radiograph interpretation placed our patient in an urgent condition thus emergency surgical management might be postponed.<sup>16,17</sup> Conversely, intra-operative findings revealed a condition that needs immediate surgical management.

### Conclusion

This case illustrates some of the potential pitfalls in the interpretation of clinical presentation and plain abdominal radiographs that may negatively impact the management of neonatal patients with obstructive ileus. An emergency case like malrotation with its propensity for volvulus is truly a potentially fatal condition and should be treated immediately. Surgeons and radiologists must always have a particularly high level of suspicion of life-threatening cases until proven otherwise.

### REFERENCES

1. Srinivas S, Reddy RK, Balraj TA, Gangadhar A. Neonatal small bowel obstruction due to malrotation: A clinical study. *Int Surg J.* 2017;4(8):2727-9.
2. Prasad GR, Aziz A. Abdominal plain radiograph in neonatal intestinal obstruction. *J Neonatal Surg [Internet].* 2017 Jan 1 [cited 2020 Feb 14];6(1). Available from: <https://www.ncbi.nlm.nih.gov/pmc/articles/PMC5224763/>
3. Mwai Jumbi T, Singh Mann M, Kipyegon Lessan J. Diagnosing ileal atresia: The role of clinical correlation and plain radiography. *Ann Afr Surg.* 2018;15(2):73-5.
4. Hamidi H, Obaidy Y, Maroof S. Intestinal malrotation and midgut volvulus. *Radiol Case Rep.* 2016;11(3):271-4.
5. Applegate KE, Anderson JM, Klatte EC. Intestinal malrotation in children: A problem-solving approach to the upper gastrointestinal series. *RadioGraphics.* 2006;26(5):1485-500.



6. Zaki M. Imaging of neonatal upper gastro-intestinal atresia beyond the esophagus in correlation with surgical findings. *Med J Cairo Univ.* 2015;2:207-14.
7. Shahjahan M, Ferdous KMN, Mitul MAR, Islam MK. Management of jejunoileal atresia : Our 5-year experience. *Chattagram Maa-O-Shishu Hosp Med Coll J.* 2013;12(3):52-5.
8. Adeniyi. Intestinal malrotation in the older child: A call for vigilance [Internet]. [cited 2020 Mar 1]. Available from: <http://www.jcsjournal.org/article.asp?issn=2468-6859;year=2017;volume=14;issue=4;page=200;epage=203;aulast=Adeniyi>
9. Balineni P, Kamal S, Manickam P, Shivaji K. Apple-peel atresia: A case report. *Int Surg J.* 2019;6(5):1821-3.
10. Sakai K, Ono S, Fumino S, Shimadera S, Iwai N. Clinical course of obstructive jaundice associated with operated meconium peritonitis in neonates. *Eur J Pediatr Surg.* 2010;20(4):222-5.
11. Gupta AK, Guglani B. Imaging of congenital anomalies of the gastrointestinal tract. *Indian J Pediatr.* 2005;72(5):403-14.
12. Amole AOD, Johnson AWBR, Adesiyun OA. The diagnostic value of the triple bubble sign in proximal jejunal atresia: A case report. *Afr J Med Med Sci.* 2003;32(1):95-8.
13. Coran AG, Caldamone A, Adzick NS, Krummel TM, Laberge JM, Shamberger R. *Pediatric surgery E-Book.* Elsevier Health Sciences; 2012. p. 1895.
14. Tackett JJ, Muise ED, Cowles RA. Malrotation: Current strategies navigating the radiologic diagnosis of a surgical emergency. *World J Radiol.* 2014;6(9):730-6.
15. Carroll AG, Kavanagh RG, Ni Leidhin C, Cullinan NM, Lavelle LP, Malone DE. Comparative effectiveness of imaging modalities for the diagnosis of intestinal obstruction in neonates and infants: A critically appraised topic. *Acad Radiol.* 2016;23(5):559-68.
16. Sigmon DF, Eovaldi BJ, Cohen HL. Duodenal atresia and stenosis. In: *StatPearls* [Internet]. Treasure Island (FL): StatPearls Publ; 2020 [cited 2020 Mar 7]. Available from: <http://www.ncbi.nlm.nih.gov/books/NBK470548/>
17. Soto JA, Lucey BC. *Emergency radiology: The requisites e-Book.* Elsevier Health Sciences; 2016. p. 429.

Follow Us on Instagram  
**@kalbemed**

